

Shear Wave Elastography for Assessment of Testicular Stiffness in Patients with Varicocele: A Prospective Comparative Study

Sabahattin Yüzkan*, Atilla Hikmet Çilengir

Department of Radiology, University of Health Sciences, Basaksehir Cam and Sakura City Hospital, Istanbul, Turkey

Abstract

Background: The purpose of this study was to use ultrasonography and shear wave elastography (SWE) to assess stiffness and volume of testes in adult patients with varicocele, to compare the results with those of normal contralateral testes of the same patients and healthy testes of control subjects. **Methods:** In this IRB-approved prospective comparative study, 58 patients with varicocele (116 testes) and 58 control patients (116 testes) were enrolled. A total of 66 testes with varicocele were added to group A, their 50 healthful contralateral testes were added to Group B, and 116 healthy control testes were added to Group C. Analysis of variance (one way ANOVA) test was used to compare groups and Student's *t*-test was used for their binary comparisons. The correlation between the testicular stiffness and volume was studied using Pearson's correlation test. **Results:** There was not a significant difference in the mean SWE values between three groups and also, between two-group comparisons ($P < 0.05$). In the mean testicular volumes, a significant difference was observed between Groups A and C ($P = 0.028$). Conversely, there was not a significant difference between Groups A and B ($P = 0.907$) or Groups B and C ($P = 0.094$). A meaningful correlation between testicular stiffness and volume was not detected for each group. **Conclusion:** A significant correlation was not determined between SWE values and varicocele, and also between SWE values and testicular volume. We advise that more studies with larger populations of patients are required to verify the effectiveness of SWE in predicting testicular parenchymal damage.

Keywords: Shear wave elastography, testis, testicular stiffness, ultrasound, varicocele

INTRODUCTION

Varicocele is the abnormal dilatation of pampiniform plexus veins.^[1] Clinical findings are usually palpable soft scrotal mass and pain. In addition, varicocele is the most frequent reason of infertility in male patients.^[1] The prevalence is approximately 15% to 20% in the general population.^[1] The prevalence increases up to 35%–44% of cases with primary infertility and 45%–81% of cases with secondary infertility.^[2] On the other hand, about 80% of varicocele cases are fertile.^[3] The harmful outcomes of varicocele on testicular volume has been reported in previous studies.^[4,5] Varicocele-associated testicular atrophy is the main indication for varicocelectomy in adolescents.^[5] Varicocele generally occurs on the left side in most patients, because of the sharp angle between left spermatic vein and left renal vein.^[6] Although the clinical investigation is the main method for the diagnosis, ultrasonography (US) is widely

used as a basic imaging modality especially in subclinical varicocele cases. Dilation of the veins to a diameter of larger than 2 mm and increased width during the Valsalva maneuver are the diagnostic criteria.^[7,8]

Shear wave elastography (SWE) is a novel, reproducible and noninvasive ultrasonographic imaging method used to evaluate the rigidity and elasticity of various tissues.^[9] It provides quantitative data for assessment of parenchymal disorders. The effectiveness of SWE in assessing the stage of fibrosis caused by parenchymal injury has been demonstrated in different organs such as the liver, kidney, prostate gland, thyroid gland, musculoskeletal system, and breast.^[10-16] Several studies have

Address for correspondence: Dr. Sabahattin Yüzkan,
Department of Radiology, University of Health Sciences, Basaksehir Cam
and Sakura City Hospital, Istanbul 34000, Turkey.
E-mail: sabahyuzkan@gmail.com

Received: 16-12-2021 Revised: 28-01-2022 Accepted: 15-02-2022 Available Online: 03-05-2022

Access this article online

Quick Response Code:



Website:
www.jmuonline.org

DOI:
[10.4103/jmu.jmu_218_21](https://doi.org/10.4103/jmu.jmu_218_21)

This is an open access journal, and articles are distributed under the terms of the Creative Commons Attribution-NonCommercial-ShareAlike 4.0 License, which allows others to remix, tweak, and build upon the work non-commercially, as long as appropriate credit is given and the new creations are licensed under the identical terms.

For reprints contact: WKHLRPMedknow_reprints@wolterskluwer.com

How to cite this article: Yüzkan S, Çilengir AH. Shear wave elastography for assessment of testicular stiffness in patients with varicocele: A prospective comparative study. *J Med Ultrasound* 2022;30:277-81.

been conducted about the effects of varicocele in testicular parenchyma and varicocele was found to change the testicular stiffness as measured by elastography.^[9,17-21]

The purpose of this study was to use SWE to assess stiffness changes of testes in adult patients with varicocele, to compare the results with those of healthy contralateral testes of the same patients and normal testes of control group patients without varicocele. Furthermore, the relationship between varicocele and testicular volume changes was evaluated.

MATERIALS AND METHODS

In this prospective controlled study, institutional review board approval was acquired from the medical ethics committee (Protocol number of Ethics Committee approval: March 27, 2021). Written informed consent was acquired from each patient before SWE, and detailed information was given about the examination.

Patient selection and study design

This prospective comparative study was performed between April 2021 and September 2021. Inclusion criteria were male gender and age over 18 years. A total of 58 cases with varicocele (116 testes) and 58 control cases (116 testes) were enrolled in the study. 8 of the patients had bilateral varicocele. 66 testes with varicocele were added to Group A, their 50 health opposite side testes were added to Group B, and 116 healthy control testes were added to Group C. The healthy individuals of control group subjects were randomly selected from the participants who had consulted for the scrotal US. In total 17 patients with a previous history of varicocelectomy, present or previous cryptorchidism, infection, hydrocele, pyocele, and abnormal testicular parenchymal echogenicity on US examination were excluded from this work. The inclusion and exclusion criteria of this study are summarized in Figure 1.

Ultrasonography and shear wave elastography examination

Patients were evaluated with US and SWE, and examinations were applied by two radiologists with more than 7 years of experience in scrotal US and 3 years of experience in SWE. The radiologists evaluated each modality independently and each

radiologist had a similar number examination. All examinations were performed by using a high-frequency (4–18 MHz) linear probe of US unit (Philips, EPIQ, The Netherlands). The pampiniform plexus veins were evaluated in supine and upright positions with and without a Valsalva maneuver. First, the side of the varicocele (if there is) was noted and dilation of the pampiniform plexus veins to a width of larger than 2 mm in diameter, and increased width during the Valsalva maneuver were diagnosed as varicocele.^[7,8] Moreover, three dimensions of each testis were measured by using light pressure in the supine position and testicular volume was calculated by the US machine using the following formula based on similar previous studies.^[17,22] Testicular volume = length × width × height × 0.523 and expressed in milliliters (ml).

After the grayscale US examination was completed, the radiologist commenced the SWE examination. Two-dimensional SWE was examined at the resting state in supine position. While conducting the SWE evaluation, the probe was held as stable as possible by using very light pressure to avoid artifacts and incorrect measurements. Sections that were obtained longitudinally were selected for the measurements and 3 regions of interest (ROI) were placed with a diameter of 8 mm onto the color-coded confidence maps and performed three measurements. Three ROI circles were set at the upper, middle, and lower poles of the testis [Figure 2]. The mediastinum testis was excluded from the ROIs. Tissue stiffness was defined with a color range from blue (low) to red (high), corresponding to 0–200 kilopascals (kPa). As in previously conducted studies, automatically generated average stiffness values were used.^[17,23] The average of the all 3 poles measurements was calculated. The results were recorded in units of kPa.

The mean SWE and testicular volume of the varicocele-positive patients were compared with those of the contralateral normal testes of the same patient and the normal testes of the control group.

Statistical analyses

Results of the mean age, testicular volume, and SWE values of all three groups are reported as the mean ± standard

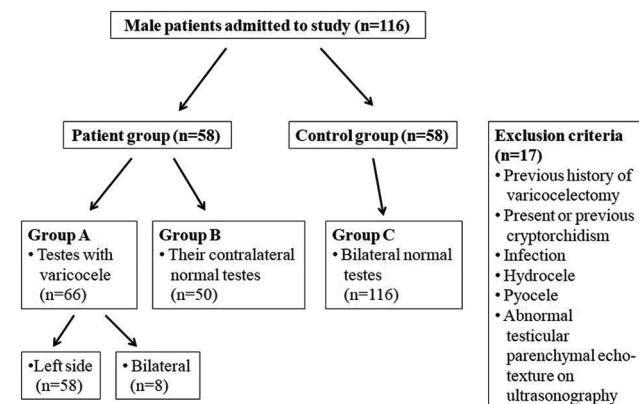


Figure 1: Flowchart of study enrollment population

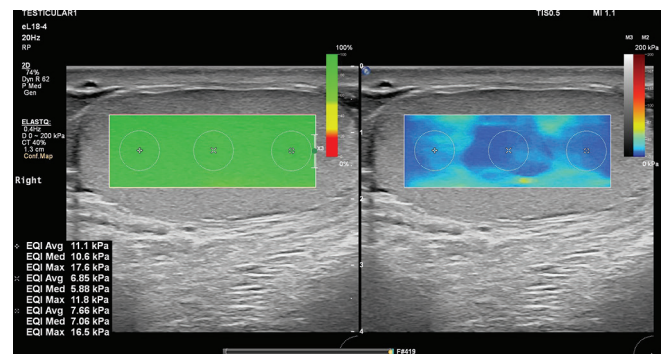


Figure 2: An example image of shear wave elastography assesment of right testis in a 46-year-old male patient without varicocele

deviation (SD). Levene's test was used to assess the homogeneity of variances based on mean \pm SD values. A parametric analysis of variance (one-way ANOVA) was used to compare all three groups and Student's *t*-test was used for binary comparisons of the groups. The correlation between the testicular stiffness and volume was studied using Pearson's correlation test (Pearson correlation coefficient = *r*). All statistical analyses were performed in SPSS (version 25.0, IBM Corp., Armonk, New York, USA) and a *P* value of lower than 0.05 was accepted to show statistical significance within a 95% confidence interval (CI).

RESULTS

In total 116 male patients (232 testes) who met the criteria were enrolled in the study. Fifty-eight of these patients had varicocele in the left side (100%, 58/58), and eight of them bilateral varicocele (13.7%, 8/58). None of the cases had isolated right side varicocele. A total of 66 testes with varicocele were included to Group A and 50 healthy contralateral testes of these patients were included to Group B. Finally, 58 patients (116 testes) with bilateral healthy testes were included to healthy control Group C.

The mean age of Group A was 33.4 ± 10.3 years (18–67), Group B was 32.4 ± 9.7 years (18–61) and the mean age of the control Group C was 33.7 ± 12 years (18–68). There was not a statistically significant difference between these 3 groups in age (*P* = 0.817). The main complaints of symptomatic cases were recurrent chronic pain in the scrotum or a palpable soft scrotal mass which indicates dilated veins. Asymptomatic cases were mainly being evaluated for reproductive health.

The SWE values were 7.90 ± 2.26 kPa in Group A, 7.44 ± 1.90 kPa in Group B, and 7.94 ± 2.07 kPa in Group C. The variances were homogenous (*P* = 0.106). There was no significant difference in the mean SWE values between the 3 groups (*P* = 0.346, *f* = 1.066). There was no significant difference between two-group comparisons (*P* = 0.248 for Group A-B, *P* = 0.133 for Group B-C, and *P* = 0.907 for Group A-C).

The mean testicular volume was 15.2 ± 4.16 mL in Group A, 15.4 ± 4.58 mL in Group B, and 16.8 ± 4.30 mL in Group C. The variances were homogenous (*P* = 0.422). The mean testicular volume values in Group A were slightly lower than that of the other groups but there was no significant difference between the 3 groups (*P* = 0.081). Moreover, a statistically significant difference was found between Groups A and C (*P* = 0.028). Conversely, there was no significant difference between Groups A and B (*P* = 0.907) or Groups B and C (*P* = 0.094).

A significant correlation between testicular stiffness and volume was not detected for each group by using Pearson correlation test (*r* = -0.039, *P* = 0.553 for Group A, *r* = 0.070, *P* = 0.628 for Group B and *r* = -0.109, *P* = 0.276 for Group C).

The mean age, testicular volume, and SWE values of all groups are shown in Tables 1 and 2.

Table 1: The mean age, testicular volume and mean shear wave elastosonography values of each group

Group	Age (year)	Volume (mL)	SWE value (kPa)
A	33.4 \pm 10.3	15.2 \pm 4.16	7.90 \pm 2.26
B	32.4 \pm 9.7	15.4 \pm 4.58	7.44 \pm 1.90
C	33.7 \pm 12	16.8 \pm 4.30	7.94 \pm 2.07

Results are showed as mean \pm SD. SWE: Shear wave elastosonography, SD: Standard deviation, kPa: Kilopascals

Table 2: Binary comparison of each group for mean testicular volume findings

Group	A versus C	A versus B	B versus C
Mean testicular volume	15.2 \pm 4.16 versus 16.8 \pm 4.30	15.2 \pm 4.16 versus 15.4 \pm 4.58	15.4 \pm 4.58 versus 16.8 \pm 4.30
<i>P</i>	0.028*	0.907	0.094

**P*-value of lower than 0.05 shows statistical significance, Values are presented as mean \pm SD in milliliters. SD: Standard deviation

DISCUSSION

SWE is a relatively new, reproducible, and noninvasive imaging method which gives information about histopathological changes in different tissues. It provides a precious quantitative evaluation of tissue stiffness and it is very useful in the evaluation of parenchymal disorders. Very few comparative studies have been conducted about the effects of varicocele in testicular parenchyma by using SWE.^[17,22]

In our study with 116 patients and 232 testes, a significant difference was not observed between the 3 groups (A, B, and C) in mean age. A significant difference was observed in the mean testicular volumes between groups A and C. However, there was not a significant difference between Groups A and B or B and C. In our study, no significant difference was observed between the 3 groups regarding to mean SWE values. Furthermore, there was no significant difference for binary comparisons in terms of mean SWE values. Furthermore, a meaningful correlation was not observed between the mean SWE value and the mean testicular volume for each group. Our study verified that the testicular volume decreases in patient with varicocele compared with healthy testes.

In a very similar prospective study by Erdogan *et al.*,^[17] 100 patients and 200 testes were examined. 50 varicocele testes, 46 contralateral healthy testes of patients, and 104 normal testes of healthy controls were added to Group A, B, and C, respectively. In this study, the mean testicular volume was 13.43 ± 4.64 mL for Group A, 14.29 ± 3.82 mL for Group B, and 15.2 ± 4.13 mL for Group C. There was no significant difference in the testicular volume between the 3 groups (*P* = 0.035, *f* = 3.424). A significant difference was observed only between Groups A and C (*P* = 0.014) in binary comparisons. The statistical results of mean testicular volume confirm our study. The mean SWE values of this study were 12.61 ± 6.23 kPa in Group A, 9.23 ± 3.23 kPa in Group B,

and 9.4 ± 4.30 kPa in Group C. Contrary to our results, they observed a significant difference in the SWE values between the 3 groups ($P = 0.001$). Furthermore, SWE values of varicocele testes were higher than control healthy testes with a statistically significant difference ($P = 0.001$). In addition, similar to our study, there was no meaningful correlation between the mean SWE values and the testicular volume for each group.

In another prospective study, Dede *et al.* evaluated the association between elastography results, serum follicle-stimulating hormone levels, and varicocele in 30 patients by using acoustic radiation force impulse elastography.^[9] This study enrolled only 30 patients with varicocele on the left side and 30 patients without varicocele. They observed a negative correlation between testicular stiffness and the varicocele grade. Comparison of the groups showed a lower testicular stiffness in patients with varicocele. In another study by Turna and Aybar,^[22] 116 testes of patients with varicocele (left side) and 58 testes of the normal control group were evaluated. This study demonstrated higher stiffness values in testes with varicocele than in the contralateral healthy testes and the testes of the normal control group ($P < 0.001$). In addition, there was no correlation between testicular stiffness and the grade of varicocele in this study ($r = 0.102$, $P = 0.423$).

Our study has a few limitations. First, we did not obtain any histological data of the patients. Second, in spite of the population was greater in our study than in the previously published studies^[9,17] we suggest that more studies with a larger sample size are needed to verify the effectiveness of SWE in predicting testicular fibrosis and parenchymal damage. Third, we did not evaluate interobserver variability because of patient privacy. SWE examination were performed only in the longitudinal plane and from three regions. The grade of varicocele was not evaluated in this study. Although there are some new papers discussing the grading system for varicocele: Dubin and Amelar introduced the varicocele grading system in 1970 when they evaluated whether preoperative varicocele size was related to semen parameter changes. The grading system classifies grade 1 varicocele as varicocele palpable only by the Valsalva maneuver, grade 2 as palpable at rest but not visible, and grade 3 as easily visible.^[24]

CONCLUSION

Our study showed a lower mean testicular volume in testes with varicocele than in the testes of normal control group with a significant difference. A correlation was not observed between SWE values and varicocele, and also between SWE values and testicular volume. We suggest that SWE may play a supportive role to grayscale US in evaluating histopathologic changes in the testis due to varicocele, but more studies with larger populations are required to confirm the effectiveness of SWE in predicting testicular parenchymal damage. Although there are significant results in the literature, the nonsignificant results require a re-evaluation of the view that varicocele is

effective on testicular stiffness. These results may also be due to society or race. We believe that studies with genetic factors and histopathological results of testicular parenchyma are needed to confirm the performance of SWE.

Financial support and sponsorship

Nil.

Conflicts of interest

There are no conflicts of interest.

REFERENCES

1. Pauroso S, Di Leo N, Fulle I, Di Segni M, Alessi S, Maggini E. Varicocele: Ultrasonographic assessment in daily clinical practice. *J Ultrasound* 2011;14:199-204.
2. Damsgaard J, Joensen UN, Carlsen E, Erenpreiss J, Blomberg Jensen M, Matulevicius V, *et al.* Varicocele is associated with impaired semen quality and reproductive hormone levels: A study of 7035 healthy young men from six European countries. *Eur Urol* 2016;70:1019-29.
3. Chu DI, Zderic SA, Shukla AR, Srinivasan AK, Tasian GE, Weiss DA, *et al.* Does varicocelectomy improve semen analysis outcomes in adolescents without testicular asymmetry? *J Pediatr Urol* 2017;13:76.e1-76.e5.
4. Jarow JP. Effects of varicocele on male fertility. *Hum Reprod Update* 2001;7:59-64.
5. Sakamoto H, Ogawa Y, Yoshida H. Relationship between testicular volume and varicocele in patients with infertility. *Urology* 2008;71:104-9.
6. Nagler HM, Grotas AB. Varicocele. In: Lipshultz LI, Howards SS, Niederberger CS, eds. *Infertility in the Male*. 4th ed. New York: Cambridge University Press; 2009. p. 331-61.
7. Chiou RK, Anderson JC, Wobig RK, Rosinsky DE, Matamoros A Jr., Chen WS, *et al.* Color Doppler ultrasound criteria to diagnose varicoceles: Correlation of a new scoring system with physical examination. *Urology* 1997;50:953-6.
8. Tsili AC, Xiropotamou ON, Sylakos A, Maliakas V, Sofikitis N, Argyropoulou MI. Potential role of imaging in assessing harmful effects on spermatogenesis in adult testes with varicocele. *World J Radiol* 2017;9:34-45.
9. Dede O, Teke M, Daggulli M, Utangaç M, Baş O, Penbegül N. Elastography to assess the effect of varicoceles on testes: A prospective controlled study. *Andrologia* 2016;48:257-61.
10. Magri F, Chytiris S, Capelli V, Alessi S, Nalon E, Rotondi M, *et al.* Shear wave elastography in the diagnosis of thyroid nodules: Feasibility in the case of coexistence of chronic autoimmune Hashimoto's thyroiditis. *Clin Endocrinol (Oxf)* 2012;76:137-41.
11. Cosgrove DO, Berg WA, Doré CJ, Skyba DM, Henry JP, Gay J, *et al.* Shear wave elastography for breast masses is highly reproducible. *Eur Radiol* 2012;22:1023-32.
12. Ozturker C, Karagoz E, Incedayi M. Non-invasive evaluation of liver fibrosis: 2-D shear wave elastography, transient elastography or acoustic radiation force impulse imaging? *Ultrasound Med Biol* 2016;42:3052.
13. Hekimoglu K, Yildirim Donmez F, Arslan S, Ozdemir A, Demir C, Yazici C. The role of shear wave elastography in the diagnosis of chronic autoimmune thyroiditis. *Med Ultrason* 2015;17:322-6.
14. Guibal A, Boularan C, Bruce M, Vallin M, Pilleul F, Walter T, *et al.* Evaluation of shear wave elastography for characterization of focal liver lesions on ultrasound. *Eur Radiol* 2013;23:1138-49.
15. Rafaelsen SR, Vagn-Hansen C, Sørensen T, Lindebjerg J, Pløen J, Jakobsen A. Ultrasound elastography in patients with rectal cancer treated with chemoradiation. *Eur J Radiol* 2013;82:913-7.
16. Hamidi C, Göya C, Hattapoğlu S, Uslukaya Ö, Teke M, Durmaz MS, *et al.* Acoustic Radiation Force Impulse (ARFI) imaging for the distinction between benign and malignant thyroid nodules. *Radiol Med* 2015;120:579-83.
17. Erdogan H, Durmaz MS, Arslan S, Gokgoz Durmaz F, Cebeci H, Ergun O, *et al.* Shear wave elastography evaluation of testes in patients with varicocele. *Ultrasound Q* 2020;36:64-8.

18. Camoglio FS, Bruno C, Peretti M, Bianchi F, Bucci A, Scirè G, *et al.* The role of sonoelastography in the evaluation of testes with varicocele. *Urology* 2017;100:203-6.
19. Abdelwahab K, Eliwa AM, Seleem MM, El Galaly H, Ragab A, Desoky EA, *et al.* Role of preoperative testicular shear wave elastography in predicting improvement of semen parameters after varicocelectomy for male patients with primary infertility. *Urology* 2017;107:103-6.
20. Yavuz A, Yokus A, Taken K, Batur A, Ozgokce M, Arslan H. Reliability of testicular stiffness quantification using shear wave elastography in predicting male fertility: A preliminary prospective study. *Med Ultrason* 2018;20:141-7.
21. Jedrzejewski G, Osemlak P, Wieczorek AP, Nachulewicz P. Prognostic values of shear wave elastography in adolescent boys with varicocele. *J Pediatr Urol* 2019;15:223.e1- 223.e5.
22. Turna O, Aybar MD. Testicular stiffness in varicocele: Evaluation with shear wave elastography. *Ultrasonography* 2020;39:350-5.
23. Ryu YJ, Choi YH, Kim JY, Cheon JE, Kim WS, Kim IO, *et al.* A preliminary study of shear-wave elastography for the evaluation of varicocele in adolescents and young adults. *Ultrasonography* 2021;41:131-9.
24. Dubin L, Amelar RD. Varicocele size and results of varicocelectomy in selected subfertile men with varicocele. *Fertil Steril* 1970;21:606-9.